

## Assessment of Diagnostic Accuracy of Real Time Shear Wave Elastography in Detecting Liver Cirrhosis Keeping Histopathology as Reference Standard

Sultan Saleem, Attique Ur Rehman Slehria, Muhammad Haris Rauf\*, Marium Sohail, Nida Taufiq\*\*, Muhammad Usman Khan

Armed Forces Institute of Radiology & Imaging/ National University of Medical Sciences (NUMS) Rawalpindi, Pakistan,

\*Combined Military Hospital Rawalakot/National University of Medical Sciences (NUMS) Pakistan,

\*\*Pak Emirates Military Hospital/ National University of Medical Sciences (NUMS) Rawalpindi Pakistan

### ABSTRACT

**Objective:** To determine the diagnostic accuracy of real-time Shear Wave Elastography (SWE) in detecting liver cirrhosis among patients suffering from diseases predisposing to it, keeping histopathology as the reference standard.

**Study Design:** Cross-sectional study.

**Place and Duration of Study:** Armed Forces Institute of Radiology and Imaging, Rawalpindi, from Jan 2018 to Jul 2018.

**Methodology:** A total of 114 patients were recruited, and relevant history taken from patients real-time shear wave elastography (SWE) of the liver was performed, followed by USG guided liver biopsy. Patients having clinically suspected diseases predisposing to hepatic fibrosis were sent to the Radiology department for ultrasound or ultrasound-guided liver biopsy. Elasticity values using shear waves of 14.9 kPa (2.23m/s) or more was taken as suggestive of cirrhosis. Elastography findings were compared with histopathology findings.

**Results:** Real-time SWE showed high diagnostic accuracy for detecting liver cirrhosis with sensitivity, specificity, positive predictive value, negative predictive value and diagnostic accuracy of 92.86%, 89.66%, 89.66%, 92.86% and 91.23%, respectively.

**Conclusion:** This study concluded that the diagnostic accuracy of RTSW elastography in detecting liver cirrhosis is relatively high.

**Keywords:** Diagnostic accuracy, Liver cirrhosis, Shear wave elastography.

**How to Cite This Article:** Saleem S, Slehria AUR, Rauf MH, Sohail M, Taufiq N, Khan MU. Assessment of Diagnostic Accuracy of Real Time Shear Wave Elastography in Detecting Liver Cirrhosis Keeping Histopathology as Reference Standard. Pak Armed Forces Med J 2022; 72(2): 590-593. DOI: <https://doi.org/10.51253/pafmj.v72i2.4168>

This is an Open Access article distributed under the terms of the Creative Commons Attribution License (<https://creativecommons.org/licenses/by-nc/4.0/>), which permits unrestricted use, distribution, and reproduction in any medium, provided the original work is properly cited.

### INTRODUCTION

It is postulated that approximately 5% of the world's population is infected with Hepatitis B. Similarly beyond 3% of the world population has HCV infection.<sup>1,2</sup> Overall, 57% of cases of hepatic cirrhosis are the result of infection by Hepatitis B (30%) or Hepatitis C (27%).<sup>4</sup> A national survey by PMRC (Pakistan Medical Research Council) suggested comparable statistics with the approximate prevalence of patients with Hbsag positive serology amounting to approximately 2.5% and of anti-HCV positive serology of approximately 4.9% among the Pakistani population, with the total chronic viral liver disease prevalence mounted to almost 11.84 million.<sup>5,6</sup>

Few studies have been carried out nationally and internationally to determine the diagnostic accuracy of real-time shear wave (RSW) elastography in evaluating the extent of fibrosis in the liver and have shown

promising results.<sup>7-9</sup> A study was done in the Radiology Department of Jinnah Postgraduate Medical Centre (JPMC) in Karachi. That study was limited to patients with Hepatitis B and C.<sup>5</sup> There is a need to expand the scope of the study to include multiple diseases predisposing to cirrhosis and to assess the diagnostic accuracy of RTSW elastography in an unspecified patient population. This subject has been addressed in a pilot study done in the Department of Diagnostic Imaging, Rhode Island, USA.<sup>8</sup> It showed the sensitivity and specificity of shear wave elastography in detecting fibrosis of METAVIR score F2 or more in an unspecified patient population, to be 80%.

Once established, shear wave elastography can become a vital, non-invasive and reliable technique for liver fibrosis assessment/cirrhosis evaluation with no adverse effects compared to liver biopsy.<sup>10</sup> The objective of our study was to determine the diagnostic accuracy of real-time shear wave elastography (SWE) in detecting liver cirrhosis among patients suffering from diseases predisposing to it, keeping histopathology as the reference standard.

**Correspondence:** Dr Sultan Saleem, Department of Radiology, Armed Forces Institute of Radiology & Imaging, Rawalpindi, Pakistan

Received: 29 Apr 2020; revision received: 17 Aug 2020; accepted: 21 Aug 2020

**METHODOLOGY**

A cross-sectional study was carried out at the Armed Forces Institute of Radiology and Imaging Rawalpindi, from Jan to Jul 2018. A sample of 114 cases was selected as per calculation from the WHO calculator with sensitivity and specificity of 80%, prevalence of 38.5%,<sup>11</sup> and precision of 10% and keeping the confidence interval at 95%. Non-probability, consecutive sampling was used for sample selection.

**Inclusion Criteria:** Patients of either gender, aged between 18-60 years, sent to the Radiology Department for ultrasound or ultrasound-guided liver biopsy, having clinically suspected diseases that may lead to hepatic fibrosis, e.g. chronic HCV/HBV infection, autoimmune hepatitis, progressive familial intrahepatic cholestasis, wilson's disease, hemochromatosis especially in thalassemic patients etc. were included in the study.

**Exclusion Criteria:** Patients with the presence of any focal hepatic lesion, e.g. HCC, hemangioma, AVM or any contraindication to liver biopsy, e.g. bleeding diathesis (platelets count <50,000 and INR>1.9) and ascites on ultrasound were excluded.

Ethical approval was sought from the Institutional Review Board (IERB Approval Certificate No. 0003). Patients fulfilling inclusion and exclusion criteria who needed an ultrasound-guided liver biopsy for confirmation of disease and extent of fibrosis were enrolled in this study after written informed consent. Patients' demographic data and detailed history were recorded on predesigned Proforma. A trainee radiologist performed RTSW elastography under the supervision of a qualified consultant radiologist using Aplio 500 Toshiba Diagnostic Ultrasound unit. Fibroscan cut-off value of 14.9 kPa (2.23 m/s) was used as a reference for the presence of cirrhosis.<sup>12</sup> Afterward, liver biopsy under ultrasound guidance was done from the same intercostal space used for elastography, and the sample was sent to the Histopathology Department, Armed Forces Institute of Pathology, Rawalpindi for modified histological activity index scoring.<sup>13</sup>

Data analysis was carried out employing the computer software SPSS 23. Quantitative variables were summarized as mean ± SD and qualitative variables were summarized as frequency and percentages. Contingency table (2x2) was used for calculating diagnostic accuracy of RTSW elastography in detecting liver cirrhosis among patients suffering from disease predisposing to it, keeping histopathology as the reference standard.

Data was used to construct receiver operating characteristic (ROC) curve and area under the curve (AUC) was calculated to contemplate likelihood ratios. The AUC values close to 1.0 indicated maximum diagnostic accuracy were considered significant.

**RESULTS**

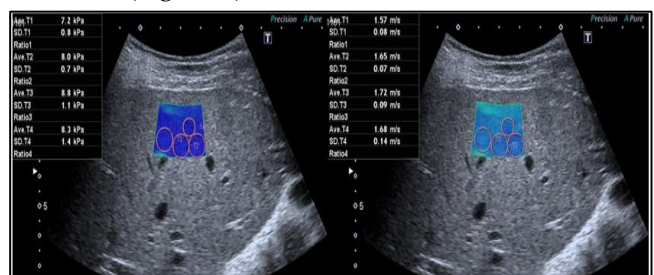
In this study, the mean age of the patients was 37.86 ± 11.98 years. The majority of patients 64 (56.14%), belonged to the age group between 18 to 40 years. Of the 114 patients, females were 67 (58.77%), males were 47 (41.23%), and the female to male ratio was 1.4:1. The distribution of patients according to disease diagnosed was shown in Table-I.

**Table-I: Distribution of patients according to diagnostic disease (n=114).**

Diagnostic Disease	No. of Patients n=114	Age %
Hepatitis B	30	26.32
Hepatitis C	61	53.51
Autoimmune Hepatitis	12	10.53
Others	11	9.65

Out of 114 patients, 58(51%) cases were positive on RTSW elastography and 56 (49%) cases were negative on RTSW elastography for cirrhosis. Out of 58 positives, 52 (90%) cases were true positives and confirmed by histopathology, while 6 (10%) cases were falsely diagnosed positive by RTSW Elastography, whose histopathology was negative for cirrhosis. Out of 56 negative cases, 52 (93%) cases were true negative with histopathology negative for cirrhosis, while 4 (7%) cases were falsely diagnosed negative by RTSW elastography whose histopathology confirmed diagnosis of cirrhosis. Sample reference elastography maps were shown as Figure-1A for non-cirrhotic and Figure-1B for cirrhotic patients.

Overall diagnostic accuracy of RTSW elastography in the detection of liver cirrhosis among patients suffering from disease predisposing to it, keeping histopathology as a reference standard WAS 92.86%, 89.66%, 89.66%, 92.86% and 91.23% for sensitivity, specificity, positive and negative predictive values respectively (Table-II). The area under the ROC curve was 0.488 (Figure-2).



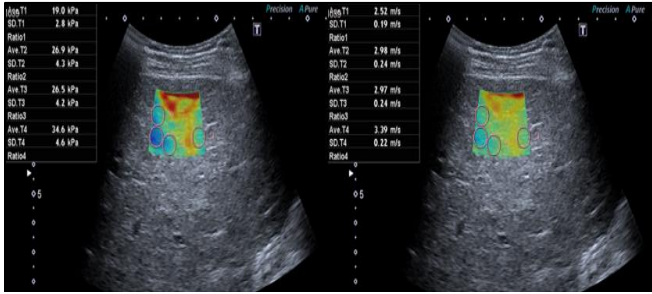


Figure-1A&1B: Shear Wave Elastography map in a patient with no Cirrhosis (A) & with Cirrhosis (B)-Elasticity was mentioned in kPa & Velocity in m/s.

Table-II: Diagnostic accuracy of RTSW Elastography in detecting liver cirrhosis among patients suffering from disease predisposing to it, keeping histopathology as reference standard.

	Histopathologically Positive	Histopathologically Negative	p-value
Positive real time shear wave elasto-graphy	52 True positive	06 False positive	0.001
Negative real time shear wave elastography	04 False negative	52 True negative	

Diagnostic Accuracy: 91.23%

Sensitivity: 92.86%, Specificity: 89.66%, Positive Predictive Value (PPV): 89.66%, Negative Predictive Value (NPV): 92.86%, Likelihood ratio-positive result: 8.98, Likelihood ratio - negative result: 0.08.

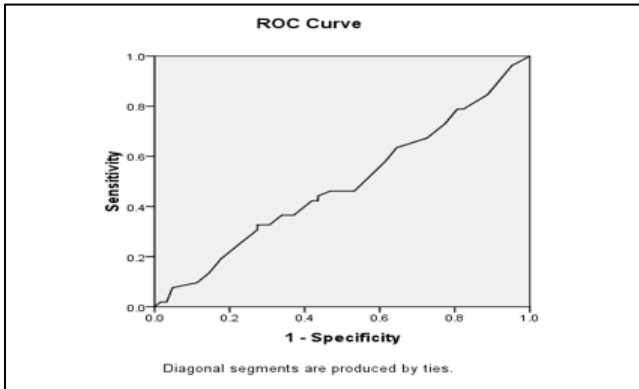


Figure-2: ROC curve (Area under the curve value (AUC)= (0.488).

**DISCUSSION**

Liver biopsy (LB) is considered the gold standard in evaluating the degree of liver fibrosis. However, since it is an invasive method that can cause pain, local haemorrhage, and even death.<sup>10</sup> It is also susceptible to inter and intra-observer variations, errors in sampling, and some other limitations.<sup>14,15</sup> Progress in medical imaging has enabled quantitative and non-invasive evaluation of liver fibrosis with various ultrasound techniques such as real-time tissue elastography (RTE), transient elastography (TE), acoustic radiation force impulse imaging (ARFI), and real-time shear wave

elastography (SWE).<sup>12-14</sup> Of these techniques, shear wave elastography (SWE) is among the newer techniques. The velocity of acoustically created shear waves in liver parenchyma is calculated and used to estimate liver stiffness. It carries the added advantage of real-time ultrasound images and colour maps based on elastography values depicting the degree of liver parenchymal stiffness. This can lead to better accuracy in the evaluation of the extent of liver fibrosis.<sup>7,15</sup>

Different techniques of elastography are being scrutinized in many meta-analyses to assess their reliability in estimating the extent of fibrosis of the liver. They have shown to have high accuracy and clinically satisfactory results in the diagnosis of liver cirrhosis; however, their accuracy in differentiating mild from moderate fibrosis of the liver is intermediate.<sup>16-18</sup> Many studies done to establish the accuracy of RTSW elastography in evaluating the extent of liver fibrosis showed broad ranges of sensitivity and specificity.<sup>19-23</sup> We have conducted this study to evaluate the reliability and diagnostic accuracy of RTSW elastography in detecting liver cirrhosis among patients suffering from disease predisposing to it, keeping histopathological results as the reference standard. This study reported sensitivity, specificity, positive and negative predictive values and diagnostic accuracy of RTSW elastography as 92.86%, 89.66%, 89.66%, 92.86% and 91.23%, respectively.

In a meta-analysis analysis 24 done in PLA General Hospital, Beijing, China in 2016 of 8 published studies including 934 patients in total, the overall sensitivity and specificity of shear wave elastography for detection of F≥2 stages of fibrosis was found to be 85.0% and 81%, respectively. AUROC curve was found to be 0.88. Overall sensitivity and specificity of shear wave elastography in diagnosing stage F≥3 was found to be 90.0% & 81.0%, respectively, which corresponds to the AUROC curve of 0.94. Overall sensitivity and specificity of shear wave elastography in detecting stage F≥4 of fibrosis was 87.0% & 88.0%, respectively, which corresponds to the AUROC curve of 0.9224.

Comparison of shear wave and transient elastography done by Ferraioli *et al*,<sup>7</sup> in University of Pavia, Italy on patients suffering from chronic Hepatitis C Virus infection keeping liver biopsy histopathological result as a reference. The LS calculated employing shear wave elastography also improved with liver fibrosis stage. In that study, values of the area under the ROC to diagnose significant fibrosis of the liver, advanced fibrosis of liver and hepatic cirrhosis were 0.92,



0.98 & 0.98, respectively. Collectively, the results of this study imply that shear wave elastography is a method with good results for the non-invasive evaluation of separate stages of fibrosis of the liver among patients suffering from chronic liver diseases.

Real-time SWE also showed better results than ARFI in a study carried out in St. Luke's Medical Center-Quezon City, Philippines for diagnosing stage F4 liver fibrosis (cirrhosis), and it also showed that accuracy, sensitivity & specificity of real-time SWE, as well as ARFI, improved as the extent of liver fibrosis advanced.<sup>25</sup>

This study showed that the diagnostic accuracy of RTSW elastography in detecting liver cirrhosis is relatively high and can significantly increase our ability to monitor liver cirrhosis and improve patient care by timely and proper treatment, which consequently reduces patient's morbidity and mortality. Moreover, it is also an easily available and non-ionizing tool. So, we recommend that RTSW elastography be used routinely as a prime modality for assessing liver cirrhosis.

### CONCLUSION

This study concluded that the diagnostic accuracy of RTSW elastography in detecting liver cirrhosis is relatively high.

**Conflict of Interest:**None.

### Authors Contributions

SS: Conception & design, literature review, data collection, data analysis, abstract & paper drafting, critical review, AURS: Paper drafting, critical review, MHR: Literature review, data collection, data analysis, MS: Data collection, data analysis, critical review, NT: Literature review, abstract & paper drafting, MUK: Literature review, abstract & paper drafting.

### REFERENCES

1. Ashraf S, Ahmed SA, Ahmed J, Ali N. FibroScore for the Non-invasive Assessment of Liver Fibrosis in Chronic Viral Hepatitis. *J Coll Physicians Surg Pak* 2012; 22(2): 84-90.
2. Lavanchy D. The global burden of hepatitis C. *Liver Int* 2009; 29(1): 74-81.
3. Longo DL. Harrison's principles of internal medicine. (18th ed. ed.). New York: McGraw-Hill. 2012; pp. 308.
4. Pakistan Medical Research Council. Prevalence of hepatitis B and C in general population of Pakistan [Internet]. 2008. Islamabad: The Pakistan Medical Research Council; 2009. Available from: [www.pmr.org.pk/Hepatitis-Survey-Data.ppt](http://www.pmr.org.pk/Hepatitis-Survey-Data.ppt) (Assessed on August 10, 2019)
5. Saldera K, Naqvi NF, Mahmood T, Shaikh SS. Shear wave elastography; assessment of liver fibrosis in a patient of chronic liver disease associated infected by hepatitis B and C. *Professional Med J* 2016; 23(1): 99-103.
6. Iijima H. Toshiba Medical Systems Corporation [Internet]. Japan: Available from: [http://www.toshibamedicalsystems.com/library/us/pdf/Approaches\\_to\\_the\\_Diagnosis.pdf](http://www.toshibamedicalsystems.com/library/us/pdf/Approaches_to_the_Diagnosis.pdf) (Assessed on August 10, 2019)

7. Ferraioli G, Tinelli C, Bello BD, Zicchetti M, Filice G, Filice C; Liver Fibrosis Study Group. Accuracy of real-time shear wave elastography for assessing liver fibrosis in chronic hepatitis C: a pilot study. *Hepatology* 2012; 56(6): 2125-2133.
8. Beland MD, Brown SF, Machan JT, Taliano RJ. A Pilot study estimating liver fibrosis with ultra-sound shear-wave elastography: does the cause of liver disease or location of measurement affect performance?. *Am J Roentgenol* 2014; 203(3): W267-W273.
9. Markiewicz-Kijewska M, Kaliciński P, Kluge P, Piatosa B, Jankowska I. Immunological factors and liver fibrosis in pediatric liver transplant recipients. *Ann Transplant* 2015; 20(1): 279-284.
10. Tatar IG, Ergun O, Kurt A, Sahin M. The role of elastosonography in the differentiation of parotid gland lesions: Report of three cases and review of the literature. *Pol J Radiol* 2014; 79(1): 398-401.
11. Poynard T, Munteanu M, Luckina E, Perazzo H, Ngo Y, Royer L, et al. Liver fibrosis evaluation using real-time shear wave elastography: applicability and diagnostic performance using methods without a gold standard. *J Hepatol* 2013; 58(5): 928-935.
12. Samir AE, Dhyani M, Vij A, Bhan AK, Halpern EF, Navarro JM, et al. Shear-wave elastography for the estimation of liver fibrosis in chronic liver disease: Determining accuracy and ideal site for measurement. *Radiology* 2015; 274(3): 888-896.
13. Jeong JY, Kim TY, Sohn JH. RTSW Elastography in chronic liver diseases: Accuracy for predicting liver fibrosis, in comparison with serum markers. *World J Gastroenterol* 2014; 20(38): 13920-13929.
14. Hong H, Li J, Jin Y, Li Q, Li W, Wu J, et al. Performance of real-time elastography for the staging of hepatic fibrosis: a meta-analysis. *PLoS One* 2014; 9(12): e115702.
15. Zeng J, Liu GJ, Huang ZP, Zheng J, Wu T. Diagnostic accuracy of two-dimensional shear wave elastography for the non-invasive staging of hepatic fibrosis in chronic hepatitis B: a cohort study with internal validation. *Eur Radiol* 2014; 24(10): 2572-2581.
16. Yoon JH, Lee JM, Joo I, Lee ES, Sohn JY, Jang SK, et al. Hepatic fibrosis: prospective comparison of MR elastography and US shear-wave elastography for evaluation. *Radiology* 2014; 273(3): 772-778.
17. Beland MD, Brown SF, Machan JT, Taliano RJ, Promrat K. A pilot study estimating liver fibrosis with ultrasound shear-wave elastography: does the cause of liver disease or location of measurement affect performance? *Am J Roentgenol* 2014; 203(3): W267-W273.
18. Tutar O, Beser OF, Adaletli I, Tunc N, Gulcu D, Kantarci F, et al. Shear wave elastography in the evaluation of liver fibrosis in children. *J Pediatr Gastroenterol Nutr* 2014; 58(6): 750-755.
19. Yoon JH, Lee JM, Woo HS. Staging of hepatic fibrosis: comparison of magnetic resonance elastography and shear wave elastography in the same individuals. *Korean J Radiol* 2013; 14(2): 202-212.
20. Huang ZP, Zhang XL, Zeng J, Zheng J, Wang P, Zheng RQ. Study of detection times for liver stiffness evaluation by shear wave elastography. *World J Gastroenterol* 2014; 20(28): 9578-9584.
21. Zheng J, Guo H, Zeng J, Huang Z, Zheng B. Two-dimensional shear-wave elastography and conventional US: The optimal evaluation of liver fibrosis and cirrhosis. *Radiology* 2015; 275(1): 290-300.
22. Tada T, Kumada T, Toyoda H, Ito T, Sone Y. Utility of real-time shear wave elastography for assessing liver fibrosis in patients with chronic hepatitis C infection without cirrhosis: Comparison of liver fibrosis indices. *Hepatology* 2015; 45(10): E122-E129.
23. Sporea I, Bota S, Gradinaru-Tascau O, Sirlir R, Popescu A, Jurchis A. Which are the cut-off values of 2D-Shear Wave Elastography (2D-SWE) liver stiffness measurements predicting different stages of liver fibrosis, considering Transient Elastography (TE) as the reference method? *Eur J Radiol* 2014; 83(3): e118-e122.
24. Li C, Zhang C, Li J, Huo H, Song D. Diagnostic accuracy of real-time shear wave elastography for staging of liver fibrosis: a meta-analysis. *Med Sci Monit* 2016; 22(1): 1349-1359.
25. Bisnar JV. Comparison of the accuracy of shear wave elastography and acoustic radiation force impulse in determining liver fibrosis among patients with chronic liver disease. *EC Gastroenterol Dig Sys* 2017; 3(1): 88-99.